

NEPHROTIC SYNDROME IN THE FIRST YEAR OF LIFE

CHRISTER HOLMBERG*

Nephrotic syndrome during the first year of life is an uncommon condition. Usually, it is caused by congenital defects in the genes coding for the proteins most important for the glomerular filter. Most of the proteins which they code for which are known today are located in the podocytes and are important for the function of the so-called slit membrane between the podocytes. In this review the most common gene defects and the diseases they cause are discussed. NPHS1, causing lack of or a defective nephrin, the main component of the slit membrane, leads to severe intrauterine proteinuria and is most common in Finland. NPHS2 defects influence podocin, which protein is important for intracellular signaling and has a scaffolding function in lipid rafts. Severe defects may cause nephrotic syndrome and an FSGS type of histology already during the first year. WT1 mutations may cause severe proteinuria and symptoms from other organs and a DMS or FSGS like histology. LAMB2 gene mutations again influence the interaction with the basement membrane and cause eye, and neurological defects in addition to proteinuria. The most important malformation syndromes with DMS and proteinuria in infancy and infections as well as therapy are also discussed.

Descriptors: CONGENITAL NEPHROTIC SYNDROME, NEPHRIN, PODOCIN, PROTEINURIA

Nephrotic syndrome during the first year of life is rare and traditionally the diagnosis has been based on histology and classified as the so-called "Finnish type" or as Diffuse Mesangial Sclerosis (DMS). Histologically the Finnish type has been characterized by dilated tubules and clinically by normal renal function for a longer time compared with DMS. The Finnish type was a lethal disease without any treatment prior to renal transplantation. During the last decade's dialysis in infancy and renal transplantation already during the first years of life have become treatment options for these children. Thus, the prognosis has radically changed.

Today, we also know a lot more about the etiology of many diseases leading to severe therapy resistant proteinuria and nephrosis during the first year

of life. It all started with the isolation of the NPHS1 gene coding for nephrin and causing Congenital Nephrosis of the Finnish type (1). The basic defect had always been suspected to be one of the basement membrane which was believed to be the main filter for the glomerular filtrate. However, nephrin was expressed on the podocytes, the epithelial cells, and was the main component of the slit membrane, which thus seems to be the main filter. Immediately research was focused on the podocyte and additional genes have been characterized, mutations of which cause proteinuria either during the first year or later in life. Table 1 shows the most important diseases causing Nephrotic Syndrome during the first year of life. Of the genetic podocyte diseases the most important ones in Europe are NPHS1, NPHS2, WT1 and LAMB2 gene mutations (2). In addition we see malformation syndromes or infections causing proteinuria during the first year. The incidence varies, for example in Finland where NPHS1 is accumulated it is by far the most common cause whereas NPHS2 is more common in France and infections in Turkey.

The glomerular filter
and the podocyte

The main constituents of the glomerular filter are the endothelium, the basement membrane and the podocyte. Normally, larger proteins for example albumin are not filtered into the urine. Proteinuria is a common symptom of renal disease and of course all the constituents of the filter have to work and their interaction has to be in order for a normal ultrafiltrate to be formed. Inflammatory diseases of the endothelium may lead to proteinuria as do diseases where the basement membrane is defective as in Alports syndrome. However, the slit membrane connecting the podocytes seems to be the main component of the filter as mutations in genes coding for its main components or intracellular components that interact with it cause severe proteinuria. Mutations in the NPHS1, NPHS2, WT1 and LAMB2 genes usually cause nephrosis early in life, whereas mutations in the ACTN4, MYH9 and TRPC6 genes cause Focal segmental glomerulosclerosis and proteinuria in adulthood (3).

*Hospital for Children and Adolescents
University of Helsinki

Address:
Christer Holmberg, professor
Hospital for Children and Adolescents
University of Helsinki
00290 HUS, Lastenlinnantie 2
FINLAND

Table 1
Nephrotic syndrome in the first year of life
Tablica 1.
Nefrotski sindrom u prvoj godini života

Podocyte dependent hereditary kidney diseases	
NPHS1 mutations	Congenital NS of the Finnish type
NPHS2 mutations	Autosomal recessive FSGS
WT1 mutations	Denys Drash syndrome
	Frasier syndrome
	FSGS
LAMB2 mutations	Pierson syndrome
	DMS & eye anomalies
	FSGS
Malformation syndromes with nephrotic syndrome	
Galloway and Mowat syndrome	
DMS and mental and/or intestinal malformations	
Infections (CMV, Syphilis, Toxoplasmosis etc.)	

NPHS1, Congenital Nephrosis of the Finnish Type

This is an autosomal recessive disease accumulated in Finland where the incidence is one in 8000 live births and where it was described in 1956 (4). The disease is characterized by intrauterine

onset of severe proteinuria and, probably because of intrauterine hypoproteinaemia, by a big placenta always exceeding 25% of the birth weight. Because of the intrauterine proteinuria the alpha-feto-protein concentration of amniotic fluid is high. The patients have severe proteinuria from birth with a serum albumin con-

centration <10 g/L and a urinary albumin concentration >20 g/L when the serum concentration is corrected to about 15 g/L. Earlier all patients died but today with early diagnosis, supportive therapy (nutrition, albumin substitution, thyroxin, anticoagulation), aggressive treatment of infections, nephrectomy and renal transplantation after 2-3 months on dialysis, growth and development are normal (5). The patients have a mutation in the nephrin gene and in Finland the main mutations are the Fin-major or Finn-minor mutations which both lead to absence of nephrin (6). Over 60 mutations have today been reported from all over the world and a few patients may react to ACE-inhibitors (sometimes combined with indomethacine) (7). Thus, non-Finnish patients should be treated for 2-3 months.

Early in life the kidneys are swollen on ultrasound and after 3-4 months the typical histology with dilated tubules can be seen. Later, when the patients go into chronic renal failure during their second year of life, kidney size is reduced and the histology becomes one of end stage renal disease (8). After renal transplantation there is no recurrence of the basic disease, but 30% of the patients homozygous to the Finn-major mutation develop nephrin antibodies leading to severe proteinuria which usually can be treated with cyclophosphamide, in severe cases combined with plasmapheresis (9).

NPHS2 gene mutations

In 2000 Boute et al. identified mutations in the NPHS2 gene as the cause of autosomal recessive steroid resistant NS, which can present already during the first year of life (10). Histologically, these children showed Focal Segmental Glomerulosclerosis (FSGS). The gene product podocin interacts with nephrin and has a scaffolding function in lipid rafts (11). The patients present with severe nephrotic syndrome, but go faster into renal failure than those with NPHS1 and the histology is one of FSGS after the first 3-4 months. Interestingly patients with a mutation in the NPHS1 gene in one and with a mutation in NPHS2 in the other chromosome show FSGS (12).

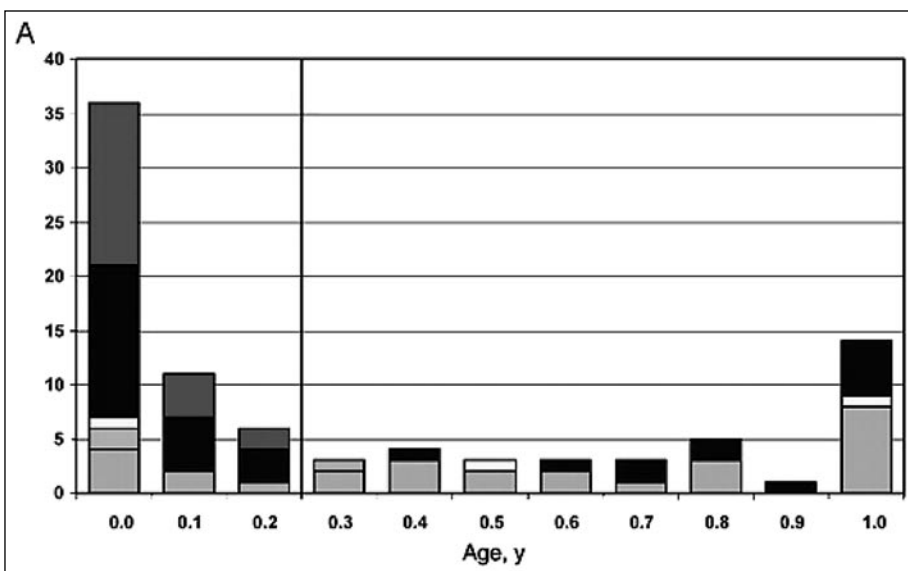


Figure 1
Age at diagnosis of NS in correlation to detected pathogenic mutation in NPHS1, NPHS2, WT1 and LAMB2 in 89 children from 80 central European and Turkish families. From Hinkes B et al. (2).

Slika 1.
Vrijeme dijagnoze nefrotskog sindroma u korelaciji s otkrivenim patogenim mutacijama NPHS1, NPHS2, WT1 i LAMB2 u 89 djece u 80 srednjeeuropskih i turskih obitelji. Od Hinkes B i sur. (2).

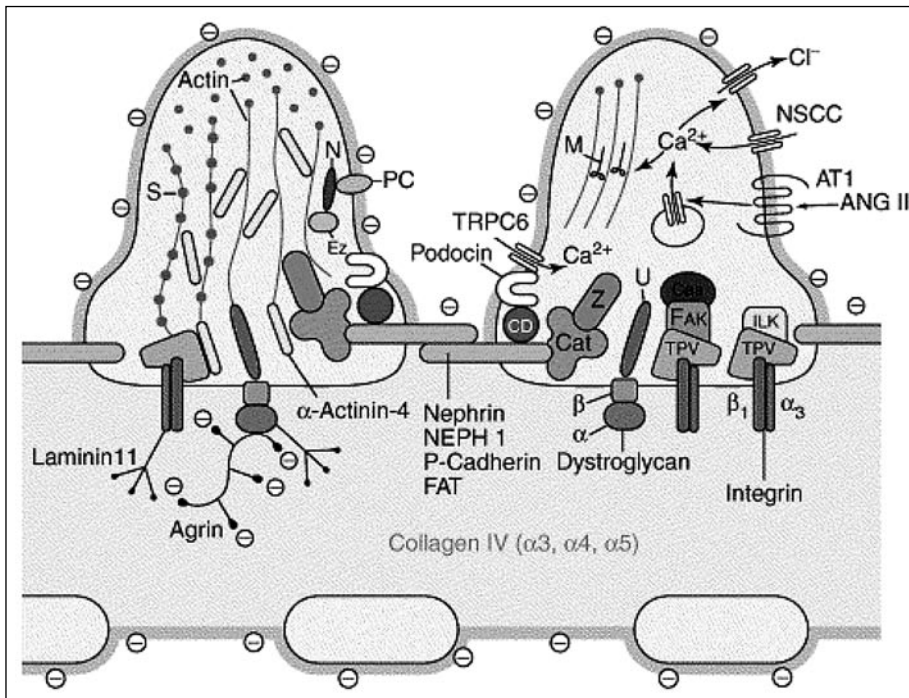


Figure 2
The glomerular filtration barrier from Kritz modification according to Endlich K et al (3). Update in podocyte biology. *Curr Opin Nephrol Hypertens*, 2001; 10: 331-40.

Slika 2.

Kritz-ova modifikacija glomerulske filtracijske membrane prema Endlich K i sur. (3). Update in podocyte biology. *Curr Opin Nephrol Hypertens*, 2001; 10: 331-40.

WT1 gene mutations

This gene encodes the transcription factor Wilms tumor suppressor gene 1 which is important for urogenital and gonadal development and activates and up-regulates nephrin. Mutations in this gene may cause the Denys Drash syndrome (with DMS, XY pseudohermaphroditism and Wilms tumors, the Frasier syndrome (defined by FSGS, XY pseudohermaphroditism and gonadoblastoma, or just NS (13-15). From a renal point of view these children may present with severe proteinuria and NS in infancy, have the other symptoms at different ages but go into renal failure faster than the NPHS1 patients once proteinuria starts. In the Denys Drash syndrome the histology is one of DMS and in Frasier's FSGS, thus it is varying but never one of the Finnish type.

LAMB2 gene mutations

Laminin beta2 is a component of the glomerular basement membrane but also found in other organs as the eye. Missense mutations in the LAMB2 gene present

with a spectrum of symptoms reaching from early onset NS to intermediate phenotypes, whereas patients with truncating mutations present with Pierson syndrome (NS, DMS, eye anomalies and mental retardation) (16, 17).

Malformation syndromes and infections

Different congenital malformations of the central nervous system, intestine, deafness, hypoparathyroidism etc. may be combined with NS during the first year of life and the histology is usually one of DMS. One of these is called the Galloway and Mowat syndrome (microcephaly, mental retardation, intestinal defects, DMS (18). Infections like CMV, syphilis, toxoplasmosis etc. may also be combined with NS at early age and should always be remembered and excluded as they can be treated medically in contrast to the other ones were the only therapy is one for chronic renal failure, ultimately renal transplantation.

Differential diagnostic work up

If an infant presents with NS infections should first be excluded and properly treated if found. One should also look for other malformations, neurological development and the caryotype. The Finnish type is characterized by intrauterine onset and thus always with a big placenta and severe proteinuria from birth. Renal function is normal during the first year of life and the child is otherwise normal. If mental retardation or malformations are present the diagnosis is one of Pierson syndrome (eye anomalies) or the other syndromic ones and the histology usually DMS. NPHS2 and WT1 mutations may lead to intrauterine onset but usually present later. The histology is DMS or FSGS. From a therapeutic point of view a biopsy is not necessary and is usually unspecific before the first 3-4 months of life. After that it can be made to verify the diagnosis which usually can be made based on the clinical picture and mutation analysis. The genes to look at are NPHS1, NPHS2, WT1 and LAMB2. Clinically the main difference is faster development of end stage renal disease in the others compared with NPHS1.

In all of these diseases good nutrition, substitution of the protein losses, anticoagulation, thyroxin supplementation and adequate nutrition are of main importance. If the diagnosis is clear and proteinuria severe nephrectomy can be performed early in centers used to dialysis in infants. After 2-3 months on dialysis when the coagulation status has normalized and protein deficiency has been corrected renal transplantation with extraperitoneal placement of the graft can be performed in children with a weight of over 9 kg. If the child not has any other defects except the renal disease, early diagnosis, sufficient and aggressive conservative therapy, early dialysis and transplantation are compatible with normal growth and development (19).

LITERATURE

1. Kestilä M, Lenkkeri U, Männikkö M et al. Positionally cloned gene for a novel glomerular protein-nephrin-is mutated in congenital nephrotic syndrome. *Mol Cell*. 1998; 1: 575-82.

2. Hinkes B, Mucha B, Vlagos C et al. Nephrotic syndrome in the first year of life: two thirds of cases are caused by mutations in 4 genes (NPHS1, NPHS2, WT1, and LAMB2). *Pediatrics*, 2007; 119: 907-19.
3. Kritz W. TRPC6 - a new podocyte gene involved in focal segmental glomerulosclerosis. *TRENDS in Molecular Medicine* Vol. 11 No. 12, 2005.
4. Hallman N, Hjelt L, Ahvenainen E. Nephrotic syndrome in the newborn and young infants. *Ann Pediatric Fenn* 1956; 2: 227-41.
5. Holmberg C, Tryggvason K, Kestilä M et al. Congenital nephrotic syndrome. In *Pediatric Nephrology* (5th ed), edited by Avner E, Harmon WE, Niaudet P. Lippincott Williams & Wilkins, Baltimore, 2004; 503-16.
6. Ruotsalainen V, Ljungberg P, Wartiovaara J et al. Nephricin is specifically located at the slit diaphragm of glomerular podocytes. *Proc Natl Acad Sci USA*, 1999; 96: 7962-7.
7. Patrakka J, Kestilä M, Wartiovaara J et al. Congenital nephrotic syndrome (NPHS1): features resulting from different mutations in Finnish patients. *Kidney Int.* 2000; 58: 972-80.
8. Saraga M, Jääskeläinen J and Koskimies O. Diagnostic sonographic changes in kidneys of 20 infants with congenital nephrotic syndrome of the Finnish type. *Eur Radiol*, 1993; 3: 49-54.
9. Kuusniemi A-M, Qvist E, Sun Y et al. Plasma exchange and re-transplantation in recurrent nephrosis of patients with congenital nephrotic syndrome of the Finnish type (NPHS1). *Transplantation*, 2007; 83: 1316-23.
10. Boute N, Gribouval O, Roselli S et al. NPHS2, encoding the glomerular protein podocin, is mutated in autosomal recessive steroid-resistant nephrotic syndrome. *Nat Genet*, 2000; 24: 349-54.
11. Huber T, Simons M, Hartleben B et al. Molecular basis of the functional podocin-nephrin complex: mutations in the NPHS2 gene disrupt nephrin targeting to lipid raft microdomains. *Hum Mol Genet*, 2003; 12: 3397-405.
12. Koziell A, Grech V, Hussain S et al. Genotyp/phenotyp correlations of NPHS1 and NPHS2 mutations in nephrotic syndrome advocate a functional inter-relationship in glomerular filtration. *Hum Mol Genet*, 2002; 11: 379-88.
13. Pelletier J, Bruening W, Li F et al. WT1 mutations contribute to abnormal genital system development and hereditary Wilms' tumor. *Nature*, 1991; 1: 144-8.
14. Barbaux S, Niaudet P, Gubler MC et al. Donor splice-site mutations in WT1 are responsible for Frasier syndrome. *Nat Genet*, 1997; 17: 467-70.
15. Mucha B, Ozaltin F, Hinkes B et al. Mutations in the Wilms' tumor 1 gene cause isolated steroid resistant nephrotic syndrome and occur in exons 8 and 9. *Pediatr Res*, 2006; 59: 325-31.
16. Hasselbacher K, Wiggins R, Matejas V et al. Recessive missense mutations in LAMB2 as a cause of isolated and non-Pierson type congenital nephrotic syndrome. *Kidney Int*, 2006; 70: 1008-12.
17. Zenker M, Aigner T, Wendler O et al. Human Laminin beta2 deficiency causes congenital nephrosis with mesangial sclerosis and distinct eye abnormalities. *Hum Mol Genet*, 2004; 13: 2625-32.
18. Galloway N, Mowat A. Congenital microcephaly with hiatus hernia and nephrotic syndrome in two sibs. *J Med Genet*, 1968; 5: 319-21.
19. Qvist E, Pihko H, Fagerudd P et al. Neurodevelopmental outcome in highrisk patients after renal transplantation in early childhood. *Pediatr Transplant*, 2002; 6: 53-62.

Sažetak

NEFROTSKI SINDROM U PRVOJ GODINI ŽIVOTA

C. Holmberg

Nefrotski sindrom tijekom prve godine života nije uobičajeno stanje. Obično je prouzročeno prirođenim genskim defektom kodiranja proteina koji imaju vrlo važnu ulogu u građi glomerulskog filtera. Najveći broj proteina koje oni kodiraju, a koji su danas poznati, smješteni su u podocitima te su vrlo važni za funkciju tzv. slit-membrane koja se prostire između podocita. U ovom pregledu raspravljani su najčešći genski defekti i bolesti koje oni izazivaju. NPHS1 izaziva nedostatak ili promjene nefrina, glavne sastavnice slit-membrane, s posljedičnom jakom intrauterinom proteinurijom. Najčešći je u Finskoj. Promjene NPHS2 rezultiraju promjenama podocina, proteina koji je važan za prijenos signala unutar stanice te ima funkciju podizača lipida. Jake promjene mogu prouzročiti nefrotski sindrom s histološkim promjenama tipa FSGS već tijekom prve godine života. Mutacije WT1 gena mogu prouzročiti jaku proteinuriju i simptome na drugim organima te histološke promjene tipa DMS i FSGS. Mutacije LAMB2 gena djeluju na bazalnu membranu s posljedičnom proteinurijom, ali uzrokuju očne i neurološke poremećaje. Raspravljani su najvažniji malformacijski sindromi s DMS i proteinurijom u dojenačkom periodu, kao i njihovo liječenje.

Deskriptori: KONGENITALNI NEFROTSKI SINDROM, NEFRIN, PODOCIN, PROTEINURIJA